96,7%

Survival rate up to 8 years of loadingusing Rescue® MegaGen short wide diameter implants

Mitsias ME (2), Kontsiotou- Siormpa E (1), and Siormpas K (1)

1. Private Dental Clinic, Larissa, Greece, siormpk@yahoo.gr

2. Private practice, Kolonaki, Athens, Greece. www.dental-center.eu

Object

Implant placement often becomes a very difficult task, due to the lack of bone in height and width respectively. Regionally this occurs more at the posterior maxilla and mandible too (1). In order to achieve successful and adequate osseointegartion, various techniques have been introduced. More specifically sinus elevation (open and close technique), vertical augmentation, distraction osteogenesis and lateral transposition of the inferior alveolar nerve. Nevertheless these techniques for various reasons, many times are not applicable or successful (2). Short implants are defined as the fixtures with equal or less of 8 mm (3). Recently the first results have been brought up to surface regarding the survival rates and the performance of them. This study presents the 8 year results of a private clinic in Larissa, Greece.

Materials and Methods

Ninety-two fixtures (Rescue® MegaGen Co, Ltd, 377-2, Kyochon-Ri, Jain-Myun, Gyeongsan, Gyeongbok, Korea) with a length between 5.0 to 8.0 mm, and a diameter of 6.0 to 8.0 were placed from 2007-2015 (4). Seventy seven patients (34 males, 43 females aged between 26-67 years of age with average age of 52,7 years were treated) participated in this private survey. From the 92 implants, seventy three were placed in maxilla and the rest nineteen were placed in mandible; 40 of these were restored with single crowns and 52 served as abutments of fixed partial dentures. Osseointegration period was standardized as 6 months for the upper arch and 3 for the lower arch. Regarding the restoration, all implants were restored using the same laboratory and technician. The superstructure design of choice was cemented porcelain fused to metal crown.

Results

From the ninety-two fixtures only 3 placed in the maxilla were not successfully integrated indicating a success rate of 95.9% in Maxilla and a 96.7% overall. They later were replaced with 3 wider implants 4 months after the removal.

Discussion

Short wide diameter implants appear as an alternative to augmentation techniques. Their advantages are: decreased cost, decreased operation time, no sophisticated surgical interventions and less complications. Their increased diameter results in an improved emergence profile which is a typical issue with standard diameter fixtures when used at a molar location. Last the increased diameter outreaches the difference in length because of the increased osseointegration surface.

Conclusions

Short wide diameter implants are a valid treatment particularly in compromised cases were an augmentative technique cannot be used, in order to have a longer implant placed. This study indicated some results as trends for the value of short implants. More studies are necessary in order these trends to become solid.

References

1. Renouard F, Nisand D. Impact of implant length and diameter on survival rates. Clin Oral Implants Res 2006;17 (Suppl 2: 35-5
2. Ferringo N, Laureti M, Fanali S. Inferior alveolar nerve transposition in conjuction with implant placement. Int J Oral Maxillofac Implants 2005; 20:610-620.
3. Fugazzotto PA. Shorter implant in clinical practice rationale and treatment results. Int J Oral Maxillofac Implants 2008; 23:487-496.
4. The Short Implant (from 5 to 7 mm in Length), Park KB, Roo KH, Jeong CW and Siormpas K, pp 267-291. Narae Publishing INC.

1. Female, 61 years old

Rescue ext. 6.0x6.0 mm

Fig 1. Panorex showing implants placement
Fig 2. Peri -apical x-ray after 5 years of function
Fig 3. Clinical aspect of impression copins
Fig 4. Clinical view of final restorations

2. Female 49 years old

Rescue ext. 2 fixtures 7.0x6.0 mm

Fig 1. Panorex showing implants placement
Fig 2. CAT-SCAN 6 years after post loading
Fig 3. Fig 3. Clinical view with final abutments
Fig 4. Clinical aspect of final restorations

3. Male 63 years old

Rescue ext. 2 fixtures 7.0x6.0 mm

Fig 1. Panorex showing implants placement
Fig 2. Peri -apical x-ray after 5 years of function
Fig 3. Clinical view with final abutment
Fig 4. Clinical view of final restorations

4. Female 37 years old

Rescue ext. 7.0x8.0 mm

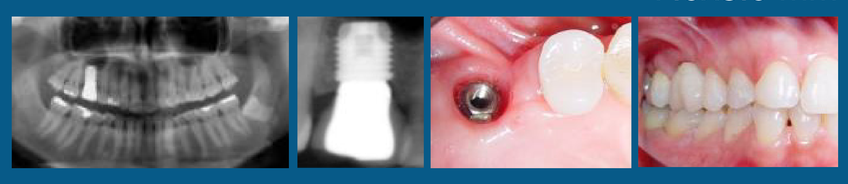

Fig 1. Panorex showing implants placement
Fig 2. Peri -apical x-ray after 7 years of function
Fig 3. Clinical view of implant at stage two
Fig 4. Clinical aspect of final restorations

Results

ARCH/sex	MALE	FEMALE	SUM	SUCCESS RATE %
MAXILLA	33	40	73	95.9%
MANDIBLE	6	13	19	100%
TOTAL	39	53	92	96.7&