100%

Success rate of the “Root Membrane” Technique using AnyRidge® implants after 3 years of loading

Siormpas K (1), Kontsiotou- Siormpa E (1), Gasparatos S (2), Kotsakis G (3), Mitsias ME (2)

1. Private Dental Clinic, Larissa, Greece, siormpk@yahoo.gr.
2. Private practice, Athens, Greece. www.dental-center.eu
3. Fellow, International Congress of Oral Implantologists (ICOI), Advanced Education Program in Periodontology University of Minnesota, MN, USA

Introduction

During the immediate post-extraction period the buccal plate of a maxillary anterior dentition is leading to significant dimensional alterations (Braut et al. 2012). Ridge preservation techniques limit but do not counter ridge resorption (Kotsakis et al. 2014). Immediate implant placement does not prevent ridge resorption (Lee et al. 2014). Loss of blood supply derived from the periodontal ligament (PDL) has been identified as a major etiologic factor for ridge resorption (Kotsakis et al. 2014). Root submergence has been utilized for over 40 years to ensure hard and consequently soft tissue dimensional stability (Salama et al. 2007). Animal studies and case reports provide proof-of-principle data on the feasibility of immediate implant placement in proximity to a retained root fragment for the strategic preservation of the natural tooth apparatus (Hurzeler, et al. 2010). The “root membrane” technique relies on the preservation of PDL, buccal plate and facial soft tissue esthetics via selective preservation of the buccal portion of the root (Mitsias et al. 2014). Recently, the first longitudinal data on implant success using this technique for immediate implant placement in maxillary anterior sites was presented (Siormpas et al. 2014).

Materials and Methods

Forty-four fixtures (N=44) (AnyRidge® MegaGen Co, Ltd, 377-2, Kyochon-Ri, Jain- Myun, Gyeongsan, Gyeongbok, Korea) with a length between 10 to 13 mm, and a diameter of 3.5 to 4.5 mm were placed from 2010-2012. Forty patients (N=40) (17 males and 23 females aged between 25-66 years of age with an average age of 48,7 years) participated in this private study. All implants were immediately loaded with a cement-retained chairside acrylic provisional restoration. The final superstructure design of choice was a cemented PFM from the same laboratory and technician for all patients. The crown of the involved tooth was removed with a conventional chamfer diamond bur under copious irrigation until the remaining tooth structure was leveled one millimeter above the osseous crest . The reason for not reducing it at the level, or even below the osseous crest was to maintain the dentogingival fibers intact to enhance soft tissue esthetics. The osteotomy sites were prepared by drilling through the long axis of the roots. This technique implements with gradual intraroot extraction (dentinotomy – osteotomy) of the palatal aspect of the root following the drilling sequence suggested by the implant manufacturer.

Result

All forty-for fixtures were successfully integrated indicating a success rate of 100%. CBCT evaluation indicated that there was no bone loss during this period of time regarding the alveolar ridge.

Conclusions

The ‘Root membrane technique’ (immediate implants placement and loading in the aesthetic zone of the maxilla), has been proven to be a successful alternative method for the aesthetic preservation of the tissues in this demanding area. More studies have to take place in order to establish this trend technique as a validated scientifically surgical procedure.

References

1.Braut, V., Bornstein, M. M., Lauber, R. & Buser, D. (2012) Bone dimensions in the posterior mandible: A retrospective radiographic study using cone beam computed tomography. Part 1--analysis of dentate sites. Int J Periodontics Restorative Dent 32: 175-184.
2. Kotsakis GA, Salama M, Chrepa V, Hinrichs J, Gaillard P. A randomized, blinded, controlled clinical study of particulate Anorganic Bovine Bone Mineral and Calcium Phosphosilicate Putty bone substitutes for alveolar ridge preservation. Int J Oral Maxillofac Implants. 2014 Jan-Feb;29(1):141-51
3. Hurzeler MB, Zuhr O, Schupbach P, et al. The socket-shield technique: a proof-of-principle report. J Clin Periodontol 2010;37(9):855-62.
4. Mitsias, M, Siormpas, K, Kontsiotou- Siormpa E, Prasad H, Garber, D, Kotsakis GA. A step-by-step description of immediate implant rehabilitation in the esthetic region utilizing the ‘’root-membrane” technique. Int J Periodontics Rest. Dent. February 2014 [In Press]
5.Salama et al. Root submergence has been utilized for over 40 years to ensure hard and consequently soft tissue dimensional stability. Int J Periodontics Restorative Dent. 2007 Dec;27(6):521-7.
6. Siormpas, K, Mitsias, M, Kontsiotou- Siormpa E, Garber, D, Kotsakis GA. Immediate implant placement in the esthetic zone utilizing the ‘’root-membrane” technique: clinical results up to 5 years post-loading. Int J Oral Maxillofac Implants. 2014 Nov-Dec;29(6):1397-05.

1. Female, 32 years old

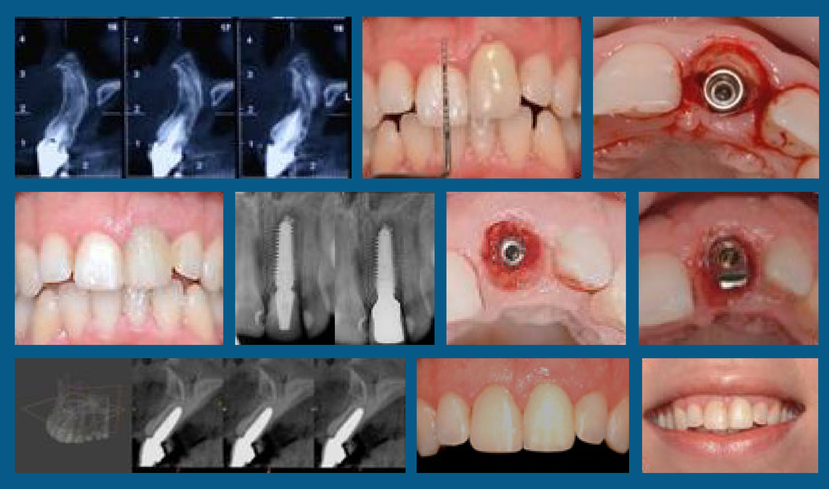

Fig 1. Initial cat-scan (horizontal fracture of tooth).
Fig 2. Initial clinical view
Fig 3. Implant placement in contact with retained part of the root
Fig 4. Provisional restoration
Fig 5. x-ray after implant placement and after the final restoration
Fig 6. Peri- implant tissue
Fig 7. Final abutment in place
Fig 8. Cat-scan 3 years after post loading
Fig 9. The final restoration in post.
Fig 10. Final esthetic result.

2. Female, 50 years old

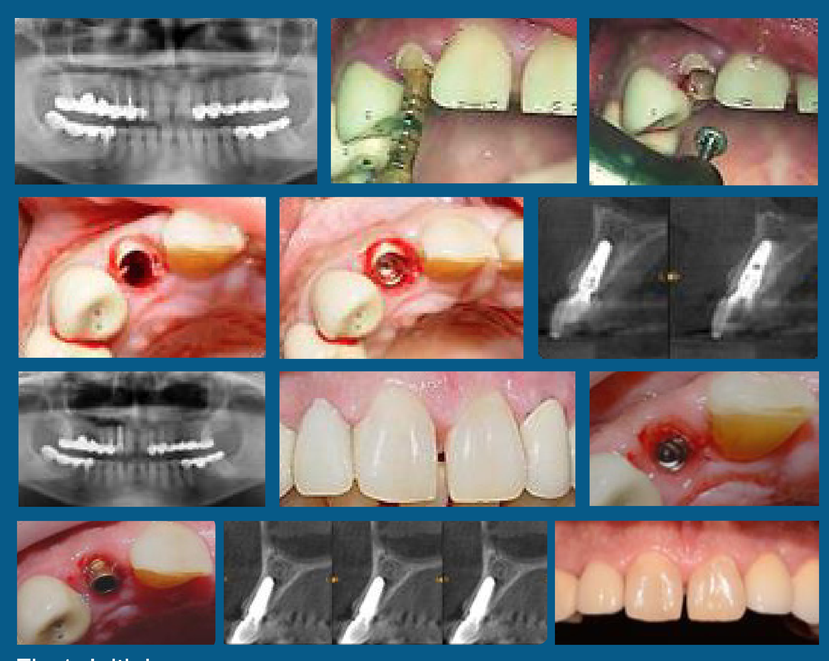

Fig 1. Initial panorex
Fig 2. initial osteotomy
Fig 3. Sequential osteotomy
Fig 4. Final osteotomy
Fig 5. Implant in place
Fig 6. Cat-scan of implant placement
Fig 7. After post loading
Fig 8. Provisional restoration
Fig 9,10. Tissue configuration – final abutment
Fig 11. Cat-scan 3 years after post loading
Fig 12. Final esthetic result

ARCH/sex	PATIENTS	ANYRIDGE IMPLANTS	SUCCESS RATE %
MALE	17	19	100
FEMALE	23	25	100
TOTAL	40	44	100