97,5%

SUCCESS RATE OF DENTAL IMPLANTS PLACED AFTER A LATERAL APPROACH SINUS AUGMENTATION PERFORMED WITH DEPROTENIZED BOVINE BONE MINERAL AND ADSORBABLE COLLAGEN MEMBRANES: A PROSPECTIVE CLINICAL AND RADIOGRAPHIC STUDY

UNIVERSITÀ DEGLI STUDI DI MILANO

Alessandro Rossi*, Tommaso Anello*, David Palombo*, Luigi Tagliatesta*,Vincenzo Capilupi*, Matteo Chiapasco*

* Unit of Oral Surgery (Head Prof. M. Chiapasco), Department of Health Sciences, San Paolo Hospital, University of Milan, Italy

OBJECTIVES

To evaluate the survival and success rates of dental implants placed in the edentulous posterior maxilla after sinus elevation performed with bovine bone mineral and resorbable collagen membranes.

MATERIALS AND METHODS

Sixty patients presenting with partial edentulism of the posterior maxilla were selected through a preoperative computed tomography with the following inclusion criteria: a) residual bone height of 2,3 to 5 mm (mean: 3,56 mm; std +/- 0,62 mm); b) residual bone width of at least 5 mm (mean: 5,8 mm; std +/- 1,09 mm); c) maintenance of an acceptable vertical intermaxillary relationship. Sixty-eight maxillary sinus augmentations were performed via a lateral approach. The sub-sinusal space was filled with deproteinized bovine bone mineral (Bio-Oss®, Geistlich Biomaterials) and a resorbable collagen membrane (Bio-Gide®,Geistlich Biomaterials) was placed over the lateral osteotomic access.

120 implants were placed 6 months after sinus augmentation and were loaded 5 months after implant placement (range 4 - 7 months). Follow-up evaluations were conducted for 24 months after prosthetic finalization.

Fig 1. Pre-operative OPT

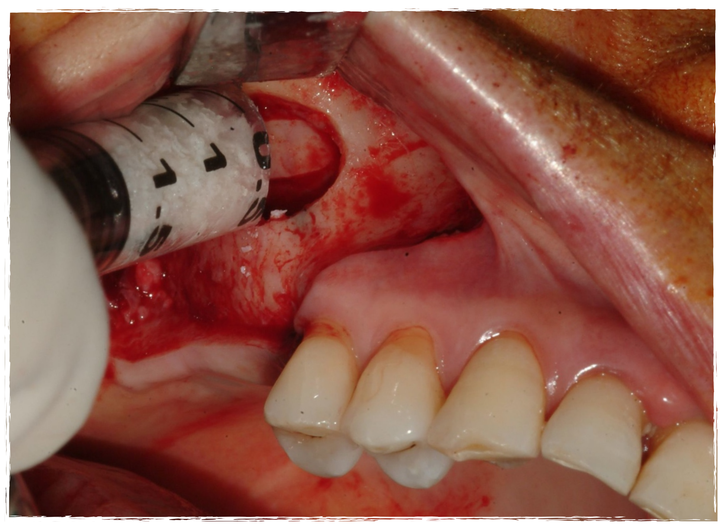

Fig 2. Maxillary sinus filled with bovine bone mineral

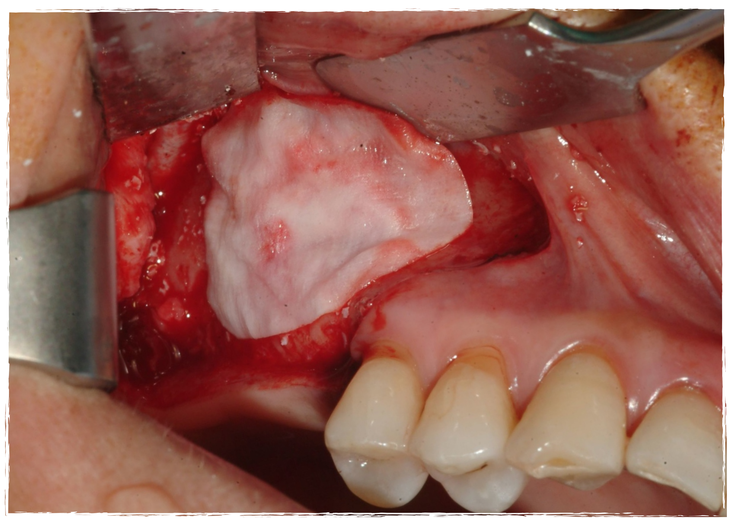

Fig 3. The sinus graft is covered with a resorbable collagen membrane

N° Implants	N° Sinus Lift	Residual Bone Height	Residual Bone Widht	Marginal Bone Loss	% Implant Success	% Implant Survival
120	68	3,56 mm (ds +/- 0,62)	5,85 mm (ds +/- 1,09)	0,85 mm (ds +/- 0,35 mm)	97.5%	100%

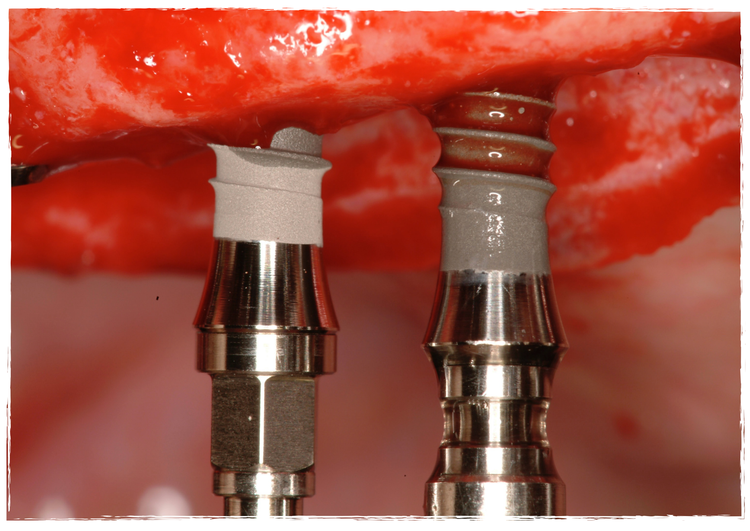

Fig 4. Delayed implant placement

Fig 5. Prosthetic load

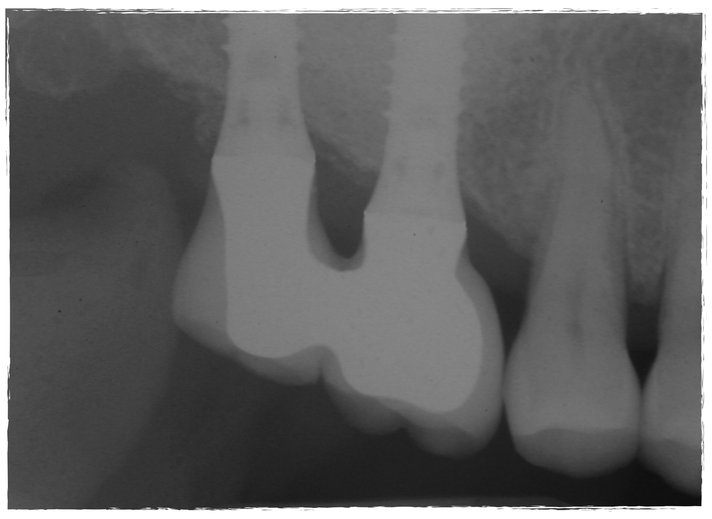

Fig 6. Periapical X-Ray 24 months after loading

RESULTS

Implant survival and success rates were evaluated according to Albrektsson et al. criteria. All sinus grafts showed full integration at the time of implant placement and during follow-up radiological assessments. The mean marginal bone loss reported around dental implants was 0,85 mm (range 0,3 - 2,2 mm; std +/- 0,35mm). Three implants survived without a successful outcome, because of excessive marginal peri-implant bone loss. No implant failed to osteointegrate or required to be removed. The overall implant survival and success rates were comparable with data reported for implants placed in native bone (100% and 97,5% respectively).

CONCLUSION

Results from this study suggest that sinus augmentation can be performed reliably using deproteinized bovine bone mineral as a sole grafting material, stabilized through a resorbable collagen membrane. No need for autogenous bone or additional grafting materials seems nowadays to be justified for the sinus augmentation procedure.

References

1. Albrektsson T, Zarb G, Worthington P, Eriksson AR. The long-term efficacy of currently used dental implants: a review and a proposed criteria of success. Int J Oral Maxillofac Implants 1986; 11-25
2. Chiapasco M, Zaniboni M, Rimondini L. Dental implants placed in grafted maxillary sinuses: a retrospective analysis of clinical outcome according to the initial clinical situation and a proposal of defect classification. Clin Oral Implant Res 2008; 19(4): 416-428.
3. Pjetursson BE, Tan WC, Zwahlen M, Lang NP. A systematic review of the success of sinus floor elevation and survival of implants inserted in combination with sinus floor elevation. Part I : Lateral Approach. J Clin Periodontol 2008; 35(8 suppl): 216-40.
4. Del Fabbro, M., Rosano, G. & Taschieri, S. (2008) Implant survival rates after maxillary sinus aug- mentation. European Journal of Oral Sciences 116: 497 – 506.